

Dig a Little Deeper: Adrenal

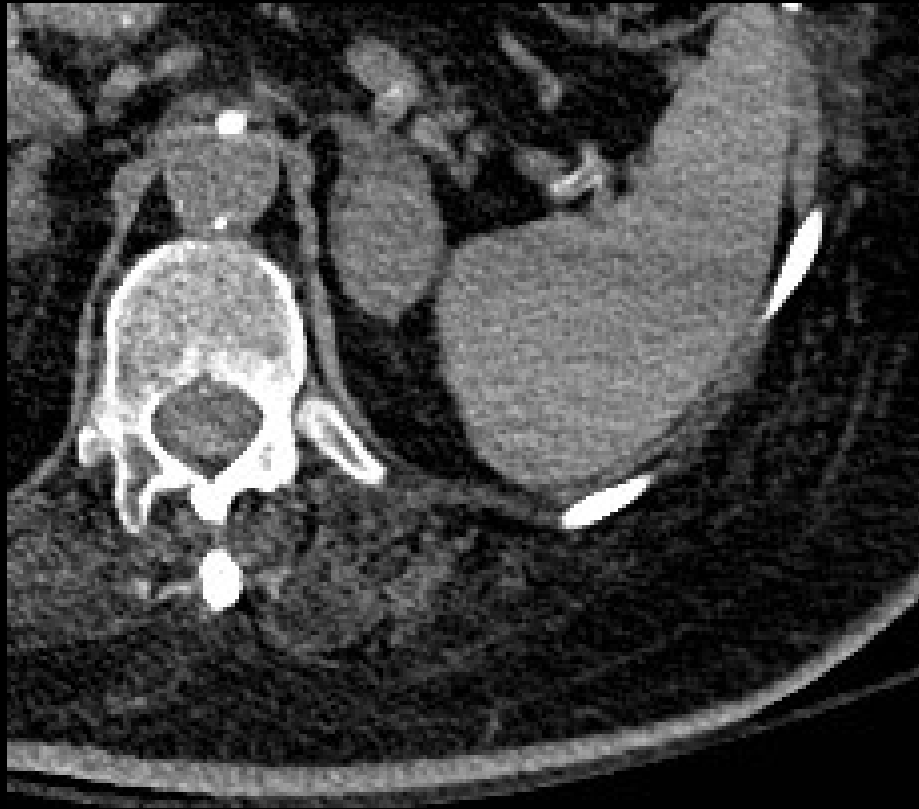Andrew D Hardie, MD

MUSC



Adrenal Protocol CT

Noncontrast

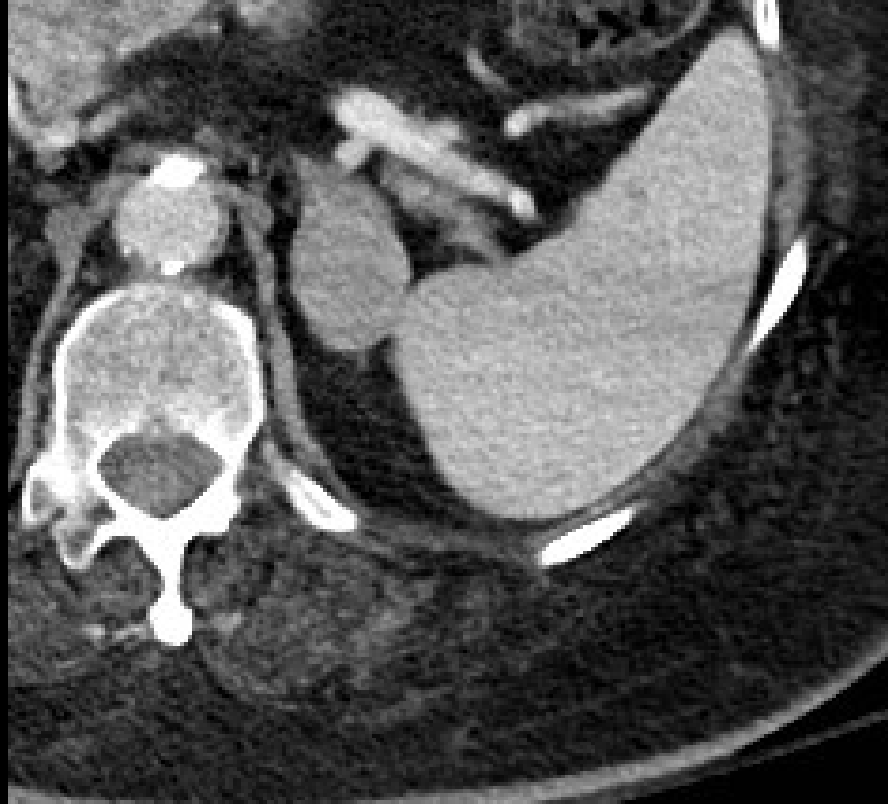

34 HU



Adrenal Protocol CT

Portal Venous Phase

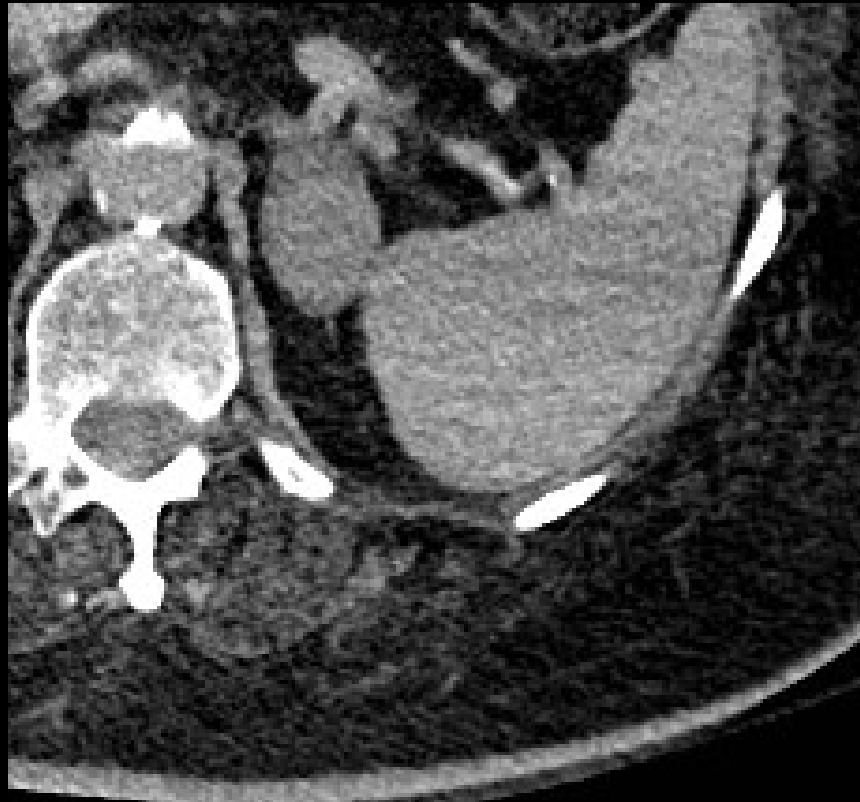

76 HU



Adrenal Protocol CT

10 Minute washout



42 HU



Washout Calculation

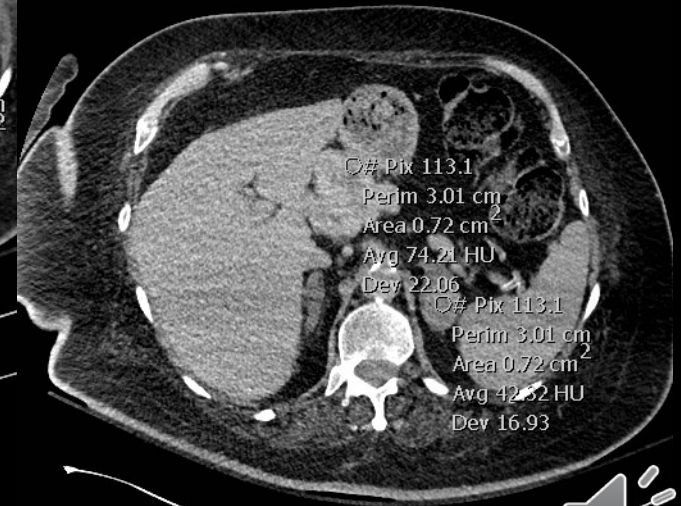
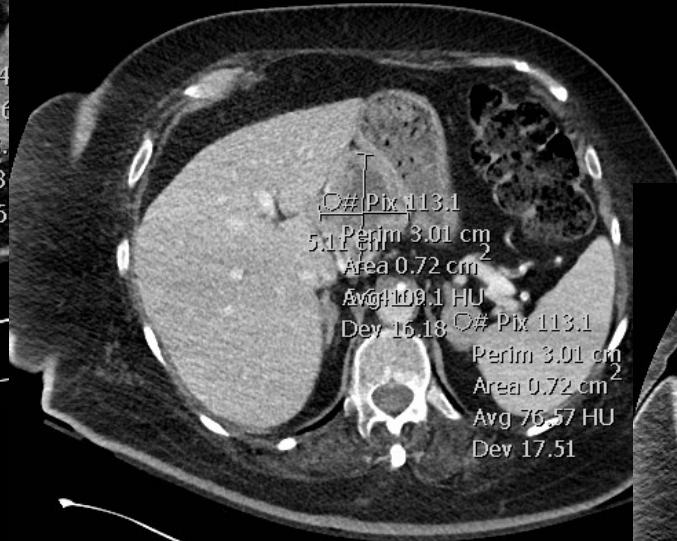
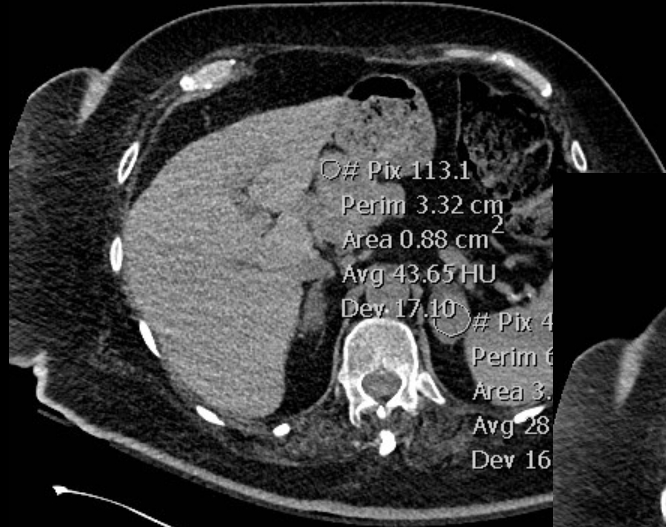
Absolute = 72%

Relative = 45%

Interpreted as consistent with adenoma



What else was on the image?



Diagnosis

Gastrointestinal Stromal Tumor (GIST)

Metastatic to the adrenal gland



Learning Point

- Adrenal protocol was designed to assess between HYPOvascular metastases and primary adrenal neoplasms (adenomas) which are usually HYPERvascular.

- Hypervascular metastases can overlap

- Choi et al. Evaluation of Adrenal Metastases from Renal Cell Carcinoma and Hepatocellular Carcinoma: Use of Delayed Contrast-enhanced CT. Radiology 2013

- Pheochromocytomas can overlap also

