

VIDEOS IN CLINICAL MEDICINE

Chest-Tube Insertion

Shelly P. Dev, M.D., Bartolomeu Nascimento, Jr., M.D.,
Carmine Simone, M.D., and Vincent Chien, M.D.

INDICATIONS

Insertion of a chest tube is indicated in either emergency or nonemergency situations. Specific indications are listed in Table 1.¹⁻³

CONTRAINDICATIONS

Published guidelines state that there are no absolute contraindications for drainage by means of a chest tube¹ except when a lung is completely adherent to the chest wall throughout the hemithorax.² Relative contraindications include a risk of bleeding in patients taking anticoagulant medication or in patients with a predisposition to bleeding or abnormal clotting profiles. Whenever possible, coagulopathies and platelet defects should be corrected with the infusion of blood products, such as fresh frozen plasma and platelets.

EQUIPMENT

Most hospitals have presterilized, packaged chest-tube–insertion trays. The key components of the tray are a scalpel with size 11 blade; several dissecting instruments, such as curved Kelly clamps or artery forceps; a 10-ml syringe and a 20-ml syringe; one small-gauge needle (size 25) and one larger-gauge needle for deeper anesthetic infiltration (size 18–21); a needle driver; scissors; one packet of strong, nonabsorbable, curved sutures of size 1.0 or larger, made from silk or nylon⁺; and a chest tube of appropriate size (see below). A commercially available pleural drainage system, such as the Pleur-evac (Teleflex Medical), should also be ready for connection after the chest tube is inserted.

From the Department of Critical Care Medicine, Sunnybrook Health Sciences Centre, University of Toronto, Toronto. Address reprint requests to Dr. Dev at the Department of Critical Care, Sunnybrook Health Sciences Centre, 2075 Bayview Ave., Office D-112, Toronto, ON M4N 3M5, Canada, or shelly.dev@sunnybrook.ca.

N Engl J Med 2007;357:e15.
Copyright © 2007 Massachusetts Medical Society.

Table 1. Indications for Chest-Tube Insertion.

Emergency

Pneumothorax

- In all patients on mechanical ventilation
- When pneumothorax is large
- In a clinically unstable patient
- For tension pneumothorax after needle decompression
- When pneumothorax is recurrent or persistent
- When pneumothorax is secondary to chest trauma
- When pneumothorax is iatrogenic, if large and clinically significant

Hemopneumothorax

Esophageal rupture with gastric leak into pleural space

Nonemergency

- Malignant pleural effusion
- Treatment with sclerosing agents or pleurodesis
- Recurrent pleural effusion
- Parapneumonic effusion or empyema
- Chylothorax
- Postoperative care (e.g., after coronary bypass, thoracotomy, or lobectomy)

Grasp the proximal free end of the chest tube with a clamp or forceps. Using another clamp or forceps, grasp the distal tip of the tube to prepare it for insertion.⁴

CHEST-TUBE SIZE

The size of the chest tube that is needed depends on the indication for the insertion of a chest tube. Table 2 provides a summary of size recommendations based on indication.⁵⁻¹¹

PREPARATION

If time permits, explain the procedure to the patient or next of kin and obtain written consent; this may not be possible when the need for chest-tube insertion is urgent.

Position the patient in either a supine or a semirecumbent position. Maximally abduct the ipsilateral arm or place it behind the patient's head. The area for insertion is approximated by the fourth to fifth intercostal space in the anterior axillary line at the horizontal level of the nipple. This area corresponds to the anterior border of the latissimus dorsi, the lateral border of the pectoralis major muscle, the apex just below the axilla, and a line above the horizontal level of the nipple—often referred to as the “triangle of safety.”² You can isolate this area by palpating the ipsilateral clavicle, then working downward along the ribcage, counting down the rib spaces. Once the fourth to fifth intercostal space is felt, move your hand laterally toward the anterior axillary line (Fig. 1). This is the area for incision; the actual insertion site should be one intercostal space above the chest-tube incision site. Mark the spot for incision on the skin with a pen or the back of a needle.

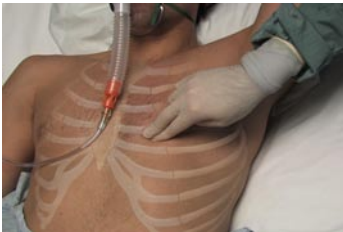

Figure 1. Locating Landmarks.

Use full barrier precautions (wash your hands and wear a sterile gown and gloves, protective eyewear, and a face mask). Create a large, sterile field on the patient's skin, using sterile gauze and 2% chlorhexidine solution. Drape the patient, exposing only the marked area. Using a 1% or 2% lidocaine solution and a 25-gauge needle, create a wheal of anesthetic in the cutaneous tissue at the marked spot. Draw up more lidocaine solution in a 20-ml syringe. Using a 21-gauge needle, anesthetize the deeper subcutaneous tissues and intercostal muscles. Locate the rib lying below the intercostal space where the tube will be inserted, and continue to anesthetize the periosteal surface. Ten to 20 ml of lidocaine solution may be used to ensure optimal analgesia.¹ While anesthetizing the rib, find the superior aspect of the rib and use this to bevel or “march” the needle on top of it. Using continued negative suction as the needle advances, with the needle beveled on top of the rib, confirm entry into the pleural space when a flash of pleural fluid enters the cham-

Table 2. Sizing of Chest Tubes on the Basis of Indication.

Indication for Chest Tube	Recommended Size of Chest Tube
Pneumothorax	
Large pneumothorax in patient in stable condition	16-French to 22-French 14-French or smaller (insert by Seldinger method)*
Large pneumothorax in patient in unstable condition Patient receiving mechanical ventilation Secondary pneumothorax	24-French to 28-French
Pleural collections	
Malignant pleural effusion Transudative effusion	Consider smaller-bore, 8-French to 16-French first* If ineffective, try larger-bore (22-French or larger)
Parapneumonic effusion Empyema	No firm recommendations 20-French or larger may be tried

* The Seldinger method of chest-tube insertion is performed with the use of 14-French or smaller chest drains usually under ultrasound guidance either at the bedside or in a radiology suite. This method is not covered in this review.

ber of the syringe. If a pneumothorax is being evacuated, the syringe may only fill with air. Stop advancing the needle and inject any remaining lidocaine to fully anesthetize the parietal pleura. Withdraw the needle and syringe completely.

INCISION AND DISSECTION

An incision 1.5 to 2.0 cm in length should be made parallel to the rib. Use the Kelly clamp or artery forceps to cut through the subcutaneous layers and intercostal muscles (Fig. 2). The path should traverse diagonally up toward the next superior intercostal space. Once you have dissected through the subcutaneous tissues, find the surface of the rib lying below this space with the dissecting instrument. Then slide the instrument straight up, until you find the top edge of the rib. Use this to bevel or balance the dissecting instrument as you dissect the intercostal muscles (Fig. 3). Once you reach the parietal pleura, gently push the dissecting instrument through it. You may also digitally penetrate the pleura to avoid puncturing adjacent lung tissue,^{3,4} using your index finger to explore the tract. Once your finger enters the pleura, withdraw the Kelly clamp. Use your finger to palpate within the pleural layer and ensure that the lung falls away from the pleura.¹ If it does not, this may indicate the presence of an adhesion, so tube insertion may be difficult. (Trocar insertion, considered dangerous, is no longer advised.⁴)

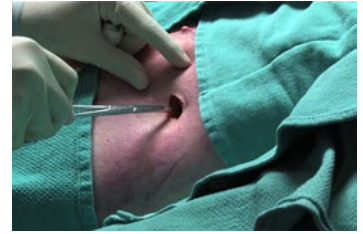


Figure 2. Dissection.

TUBE INSERTION

Once the distal tip of the tube has passed through the incision, unclamp the Kelly clamps or forceps and advance the tube manually. Aim the tube apically for evacuation of a pneumothorax and basally for evacuation of any fluid.¹⁻³

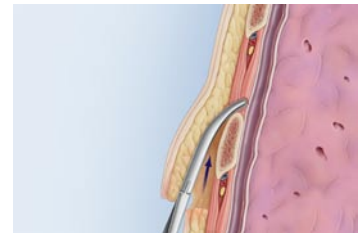


Figure 3. Positioning the Dissection Instrument.

SECURING THE TUBE

Mattress or interrupted sutures should be used on both sides of the incision to close the ends. Use the loose ends of the sutures to wrap around the tube and tie them off, anchoring the tube to the chest wall.¹ Tape the tube to the side of the patient and wrap a petroleum-based gauze dressing around the tube. Cover this gauze with several pieces of regular sterile gauze, and secure the site with multiple pressure dressings.

Purse-string sutures are not recommended owing to poor cosmetic results and increased risk of skin necrosis; the seal they provide does not prevent air leaks.³

Connect the distal end of the chest tube to a sterile pleural drainage system, such as the commercially available Pleur-evac. Once the tube is connected, unclamp the distal end; if there is a pneumothorax, bubbling may be seen. If there is a large pleural effusion, it will begin collecting. Do not reclamp the chest tube, once released, unless the pleural drainage system is being changed. Reclamping the tube may lead to the redevelopment of a pneumothorax and may create a tension pneumothorax.

CHEST RADIOGRAPH CONFIRMATION

Once you have secured the chest tube, obtain an anterior-posterior chest radiograph to confirm placement, which can be done by identifying the radio-opaque line along the tube. If the proximal drainage hole is outside the pleural space, drainage may be ineffective and an air leak may result. In this circumstance, the tube should be removed and a new chest tube inserted.

COMPLICATIONS

The most important complications associated with chest-tube insertion^{1-3,9} include bleeding and hemothorax due to intercostal artery perforation, perforation of visceral organs (lung, heart, diaphragm, or intraabdominal organs), perforation of ma-

REFERENCES

1. Miller KS, Sahn SA. Chest tubes: indications, technique, management and complications. *Chest* 1987;91:258-64.
2. Laws D, Neville E, Duffy J. BTS guidelines for the insertion of a chest drain. *Thorax* 2003;58:Suppl 2:ii53-ii59.
3. Tang ATM, Velissaris TJ, Weeden DF. An evidence-based approach to drainage of the pleural cavity: evaluation of best practice. *J Eval Clin Pract* 2002;8:333-40.
4. Hyde J, Sykes T, Graham T. Reducing morbidity from chest drains. *BMJ* 1997;314:914-5.
5. Baumann MH. What size chest tube? What drainage system is ideal? And other chest tube management questions. *Curr Opin Pulm Med* 2003;9:276-81.
6. Parulekar W, Di Primo G, Matzinger F, Dennie C, Bociek G. Use of small-bore vs large-bore chest tubes for treatment of malignant pleural effusions. *Chest* 2001;120:19-25.
7. Antunes G, Neville E, Duffy J, Ali N. BTS guidelines for the management of malignant pleural effusions. *Thorax* 2003;58:Suppl 2:ii29-ii38.
8. American Thoracic Society. Management of malignant pleural effusions. *Am J Respir Crit Care Med* 2000;162:1987-2001.
9. Light RW. Parapneumonic effusions and empyema. *Proc Am Thorac Soc* 2006;3:75-80.
10. Davies CWH, Gleeson FV, Davies RJO. BTS guidelines for the management of pleural infection. *Thorax* 2003;58:Suppl 2:ii18-ii28.
11. Baumann MH, Strange C, Heffner JE, et al. Management of spontaneous pneumothorax: an American College of Chest Physicians Delphi consensus statement. *Chest* 2001;119:590-602.

Copyright © 2007 Massachusetts Medical Society.

major vascular structures such as the aorta or subclavian vessels, intercostal neuralgia due to trauma of neurovascular bundles, subcutaneous emphysema, reexpansion pulmonary edema, infection of the drainage site, pneumonia, and empyema. There may be technical problems such as intermittent tube blockage from clotted blood, pus, or debris, or incorrect positioning of the tube, which causes ineffective drainage.

TIMING OF CHEST-TUBE REMOVAL

The timing of chest-tube removal depends on the indication for insertion of the chest tube.

For a pneumothorax, bubbling must have ceased and the lung must be fully expanded on chest radiograph before the tube can be removed. If suction is being used to evacuate a pneumothorax, most physicians will use a trial of underwater seal to ensure that the lung stays expanded without suction. Practice differs greatly among physicians with regard to duration of observation after air leak cessation and before removal of the tube and whether or not to clamp the tube before removal to rule out a persistent air leak.¹¹ On the basis of available data, most physicians would obtain a chest radiograph 12 to 24 hours after the last observed evidence of an air leak to ensure that the lung stays fully expanded before tube removal. Because opinion and practice are clearly divided on the need for clamping the drain before tube removal, no strong recommendation can be made here.

If placement was for any pleural fluid drainage, once the drainage volume is less than 200 ml in a 24-hour period,^{3,5} the fluid is serous, the lung has re-expanded on the chest film, and the patient's clinical status has improved, the chest tube may be removed.

If the patient's condition fails to improve after chest-tube insertion, a respirologist or a thoracic surgeon should be consulted for more definitive management, such as fibrinolytic therapy or surgical decortication.^{8,9}

TECHNIQUE OF TUBE REMOVAL

The major concern with removal of a chest tube is the risk of pneumothorax during removal. Again, physician practice differs with respect to the point in the respiratory cycle at which the tube is removed: during end-inspiration or end-expiration. Neither has been shown to be superior in the prevention of pneumothorax.⁵ When preparing to remove the tube, two people may need to participate so that one can instruct the spontaneously breathing patient and pull the tube while the other can quickly occlude the insertion site. Cut the skin sutures, using sterile technique. Have additional strong nylon or silk sutures ready in case additional sutures are required to seal the hole. Sterile petroleum-based and regular gauze should also be ready.

Instruct the spontaneously breathing patient to perform a forced Valsalva maneuver or to inhale to total lung capacity after a full exhalation. If the patient is being fully mechanically ventilated, removal should be timed to end-expiration. One operator can pull the tube out while the other quickly occludes the site with gauze, adds additional sutures to close the opening, and secures the site with a pressure dressing. A chest radiograph 12 to 24 hours after removal is recommended^{1,3}; this should be done sooner if there is clinical suspicion of a residual air leak or a new pneumothorax.

Caution must be exercised when removing a chest tube from any patient receiving mechanical ventilation. This is of particular importance for patients with high oxygen or positive end-expiratory pressure requirements, chronic lung disease, or any additional reasons for persistent air leaks or recurrent pneumothoraces. In these cases, highly experienced physicians should supervise the decision to remove a chest tube.

No potential conflict of interest relevant to this article was reported.