

## Thoracostomy

---

### I. INDICATIONS/CONTRAINDICATIONS

#### A. Indications

1. Tension pneumothorax
2. Large simple pneumothorax
3. Penetrating thoracic wound with concurrent need for positive-pressure ventilation
4. Hemothorax
5. Symptomatic pleural effusion (recurrent, following thoracentesis)
6. Empyema
7. Chylothorax

#### B. Contraindications

1. Coagulopathy
  - a. Correct prior to nonemergent thoracostomy.
  - b. Risk of hemorrhage must be accepted with tension pneumothorax.
2. Inability to aspirate fluid or air to confirm a patent pleural space
  - a. This dictum holds in all circumstances except a penetrating thoracic wound with need for positive-pressure ventilation.
  - b. Attempted tube placement in the presence of an obliterated pleural space risks pulmonary injury and potentially fatal hemorrhage.
  - c. Aspiration is most conveniently performed through the thoracostomy incisional wound immediately prior to tube placement.
  - d. Aspiration is most important when an apparent effusion presents as "white-out" on chest radiograph, and its free-flowing nature cannot be confirmed radiographically. Such an apparent effusion may in reality be solid tumor; blunt dissection into such tumor may have devastating hemorrhagic consequences.

### II. EQUIPMENT

#### A. Needle thoracostomy

1. 14- to 16-gauge catheter over needle
2. 23-gauge butterfly needle (infants)

#### B. Tube thoracostomy

1. Intravenous catheter, tubing, and fluid
2. Supplemental oxygen
3. Monitors (ECG, pulse oximeter)
4. Povidone-iodine solution for antiseptic skin preparation
5. Sterile syringes and infiltrating needles
6. Local anesthetic
7. Scalpel with #10 or #15 blade
8. Forcep
9. Curved clamp

10. 24- to 40-French thoracostomy tube
  - a. Notes:
    - i. 32- to 40-French thoracostomy tubes are placed in trauma settings to evacuate acute hemothorax potentially containing clots. The largest diameter tube accommodated by the intercostal space is used in this circumstance.
    - ii. For infants and children, see Table A9-1.
11. Underwater-seal drainage system
12. Needle holder
13. 0 -silk or -polypropylene suture on cutting needle
14. Suture scissor
15. 1/4-inch-wide adhesive tape strips or "cable ties" with applicator
16. Sterile 4 × 4 gauze sponges
17. Vaseline gauze
18. Povidone-iodine antiseptic ointment
19. 4-inch-wide impervious tape strips
20. 1-inch-wide adhesive tape
21. Resuscitation cart

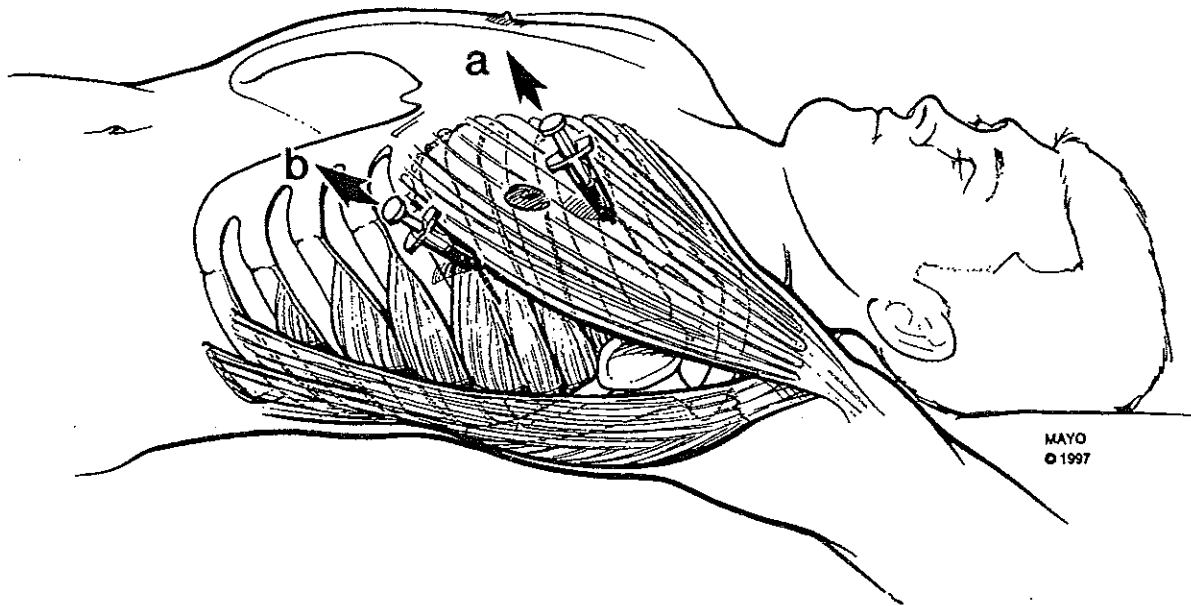
### **III. TECHNIQUE**

#### **A. Analgesia/Sedation**

1. Tube thoracostomy is a painful procedure. In nonemergent and semiurgent circumstances, intravenous narcotic analgesia and a benzodiazepine should be titrated to effect as hemodynamic and respiratory status allow. Local anesthetic should be infiltrated generously throughout the tube thoracostomy tract.

#### **B. Preliminary needle thoracostomy (Fig. A9-1)**

1. Notes:
  - a. This procedure is indicated prior to tube thoracostomy for rapid temporizing treatment of tension pneumothorax.
  - b. Although classically performed anteriorly in the midclavicular line at the second intercostal space, needle thoracostomy may be performed in the midaxillary line at the fifth intercostal space. The former position necessitates that the pectoralis major muscle and possibly breast tissue be penetrated before the intercostal space. The latter position places the needle in the auscultatory triangle posterior to the pectoralis and anterior to latissimus dorsi muscles; only the thin serratus anterior muscle need be penetrated prior to the intercostal space.
2. Don cap, mask, and sterile gloves.
3. Quickly prepare the chosen access site with povidone-iodine solution.
4. Advance 14-gauge catheter over needle with attached syringe immediately over the superior aspect of the rib while aspirating.
5. When air is aspirated, advance catheter completely, and withdraw needle and syringe. Withdraw catheter following completion of tube thoracostomy.
6. Note: 1 mL of saline in the aspirating syringe allows access of intrapleural air to be recognized as bubbles.



*Figure A9-1.* Sites for needle thoracostomy. (A) Second intercostal space, midclavicular line. (B) Fifth intercostal space, midaxillary line. The latter is also the site for the incision for placement of a thoracostomy tube and necessitates transgression of much less chest wall musculature and no breast tissue. By permission of the Mayo Foundation.

C. Preparation

1. Provide supplemental oxygen.
2. In nonemergent circumstances, establish intravenous access, electrocardiographic monitoring, and pulse oximetry.
3. Assemble the following nonsterile materials: underwater-seal drainage system, 1/4-inch-wide strips of adhesive tape or “cable-ties” to secure thoracostomy tube to drainage system, 4-inch-wide impervious tape strips to secure dressing.
4. Ensure adequate lighting.
5. Place patient in supine position with ipsilateral arm extended.
6. Don cap, mask, and sterile gloves.
7. Paint patient’s anterior and lateral chest wall with povidine-iodine antiseptic solution. Remove gloves.

*Fundamental Critical Care Support*

---

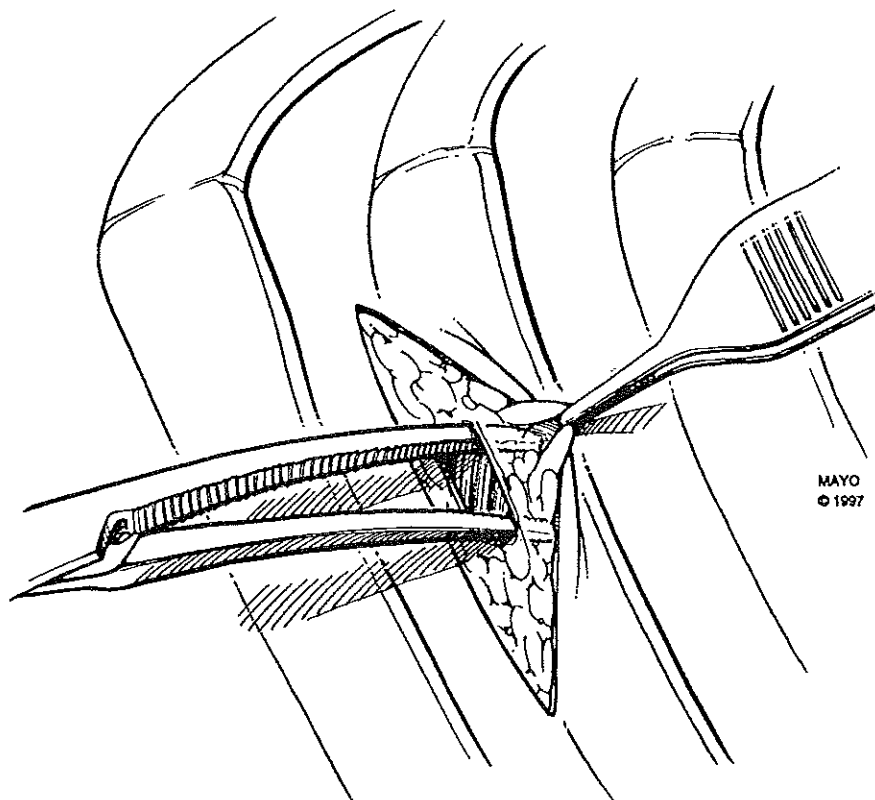
8. Don sterile gown and gloves.
9. On a sterile work space, lay out from left to right the following sterile instruments and materials in sequence: syringe with infiltrating needle loaded with local anesthetic, scalpel with blade, forcep, curved clamp, thoracostomy tube, needle holder loaded with suture, suture scissor, dressing comprised of gauze 4 × 4 sponges, petroleum jelly gauze, and povidone-iodine antiseptic ointment. These instruments and materials will be used in the sequence specified.

D. Insertion

<u>Instrument</u>	<u>Maneuver</u>
1. Syringe and needle with local anesthetic	<ol style="list-style-type: none"><li>a. Raise cutaneous wheal at incision site.</li><li>b. Deeply infiltrate underlying subcutaneous tissue.</li></ol>
2. Scalpel	<ol style="list-style-type: none"><li>a. 3-cm incision at position <i>B</i> in Figure A9-1 through the skin and subcutaneous tissue of the fifth intercostal space.</li><li>b. Deepen incision to level of chest wall musculature. Note: The skin incision parallels the intercostal space. It should be placed one interspace below the intended level of pleural entry so that a tract deep to subcutaneous tissue can be created for the tube. This tract closes spontaneously upon tube removal.</li></ol>
3. Syringe and needle with local anesthetic	<ol style="list-style-type: none"><li>a. Through wound, infiltrate subcutaneous tissue cephalad to incision.</li></ol>
4. Forcep	<ol style="list-style-type: none"><li>a. Using left hand, retract subcutaneous tissue cephalad away from chest wall to create tension at junction of subcutaneous tissue and chest wall musculature (Fig. A9-2).</li></ol>
5. Curved clamp	<ol style="list-style-type: none"><li>a. Continue to apply above traction with forcep.</li><li>b. With curved clamp in right hand, spread at junction of subcutaneous tissue and chest wall musculature to open this plane (Fig. A9-2).</li></ol>
6. Syringe and needle with local anesthetic	<ol style="list-style-type: none"><li>a. Through incisional wound, infiltrate musculature and pleura of fourth intercostal space.</li><li>b. Advance needle into pleural space while aspirating syringe.</li><li>c. Confirm presence of air or fluid in the pleural space.</li></ol>

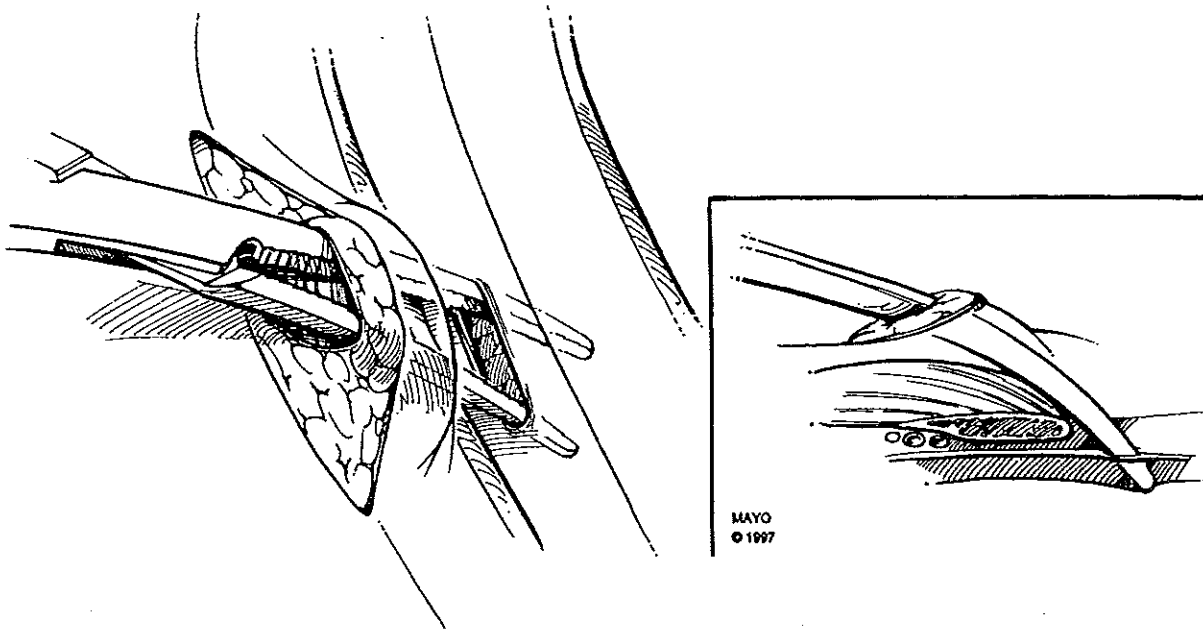
7. Curved clamp
  - a. With curved clamp in right hand, hold tips against superior aspect of fifth rib with concavity of clamp facing pleural space.
  - b. Intercostal dissection must be performed immediately superior to a rib to avoid injury to the neurovascular bundle that lies inferior to each rib.
  - c. Advance curved clamp through musculature (serratus anterior and intercostal muscles) and pleura into the pleural space (Fig. A9-3). Note: This maneuver may need to be forceful but must always be restrained. A dramatic loss of resistance will signal entry into the pleural space and will be followed by egress of fluid and/or air.
  - d. Ensuring that the tips of the clamp remain on the superior aspect of the fifth rib, widely separate the jaws of the clamp to create a generous opening through the serratus anterior muscle, intercostal muscles, and pleura.
  - e. Insert the left index finger into the pleural space as the clamp is withdrawn. Palpation of the smooth pleura confirms the intrapleural location. Sweep the finger through 360° to ensure the absence of adhesions between parietal and visceral pleura. Such adhesion and obliteration of the pleural space would predispose to pulmonary injury during tube insertion.
  
8. Thoracostomy tube
  - a. Keep the left index finger in the pleural space.
  - b. With the right hand, advance the thoracostomy tube over the tip of the left index finger into the pleural space (Fig. A9-4). Passage of the tube over the tip of the intrapleural index finger ensures intrapleural placement of the tube.
  - c. Advance the tube until resistance is encountered (approximately 15 to 25 cm). The last sidehole of the tube should reside 2 cm within the pleural cavity. Ideally, the tip of the tube lies at the pleural apex.
  
9. Waterseal drainage system
  - a. Connect the thoracostomy tube to the drainage system.
  
10. Needle holder and suture
  - a. Place a suture of 0-nonabsorbable material through the wound on either side of the thoracostomy tube.
  - b. Tie each suture to close the wound.
  - c. Tie each suture about the thoracostomy tube to secure it.
  - d. Place additional sutures as necessary to close the wound.
  
11. 1/4-inch adhesive tape or "cable ties"
  - a. Secure connection between chest tube and drainage system tubing (Fig. A9-5).

- b. Tape should never be placed in such a manner as to obscure the connection from view. One must be able to see that the connections are intact at all times.
  
  - 12. Dressing of gauze, 4 x 4 sponges, petroleum jelly gauze, povidone-iodone ointment, and impervious tape
    - a. Place dressing over thoracostomy site.
    - b. Secure dressing with impervious tape
  
  - 13. 1-inch adhesive tape
    - a. Secure chest tube and drainage system tubing to patient's trunk.
- 

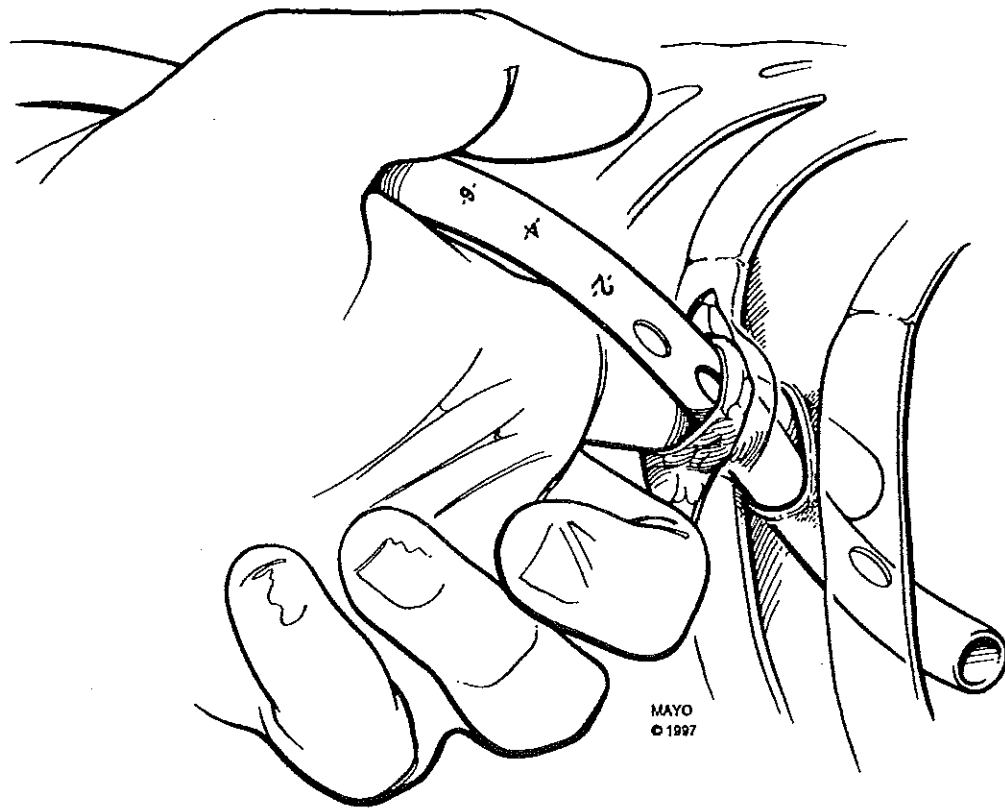


---

**Figure A9-2.** Retraction of skin and subcutaneous tissue with blunt dissection of subcutaneous tissue from chest wall musculature superior to incisional wound. By permission of the Mayo Foundation.



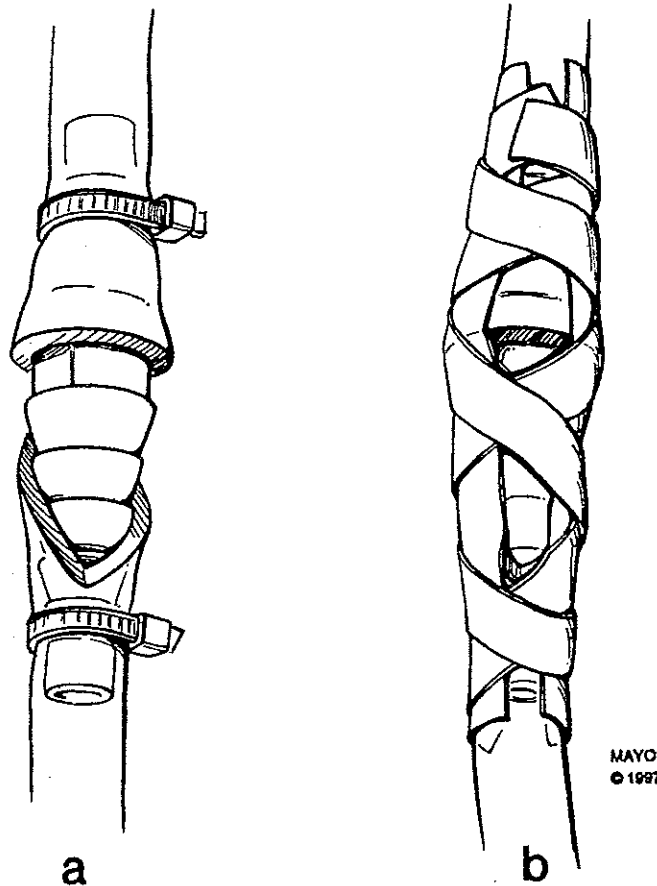
*Figure A9-3.* The curved clamp has been advanced into the superior aspect of the incisional wound and advanced through the intercostal musculature and pleura at the superior margin of the fifth rib. The jaws of the clamp are then spread to create a pleural opening. The opening should be generous enough to simultaneously admit a finger and the thoracostomy tube. *Insert* shows the path of the curved clamp in cross-section. By permission of the Mayo Foundation.



---

*Figure A9-4.* The left index finger replaces the curved clamp and remains within the pleural space as the thoracostomy tube is advanced over the tip of the finger, ensuring intrapleural location. By permission of the Mayo Foundation.





*Figure A9-5.* The thoracostomy tube and tubing from the draining system are secured about a conical connecting adaptor with “cable ties” (a) or strips of adhesive tape placed longitudinally and in a spiral fashion (b). By permission of the Mayo Foundation.

E. Pleural decompression

1. Adjust suction to 20 cm H<sub>2</sub>O.
2. Consider prophylactic antibiotic coverage.

F. Thoracostomy tube monitoring

1. A thoracostomy tube should be monitored frequently with portable chest radiography to ensure appropriate tube placement and the absence of iatrogenic pneumothorax. The last sidehole of the thoracostomy tube lies on a radiopaque line and is thus visible on the radiograph as a gap in this line; the gap should always appear well within the pleural space.
2. Patency of the chest tube is assured by the presence of a to-and-fro movement of fluid with respiration (respiratory variation). Respiratory variation may be detected within the thoracostomy tube, the tubing of the collection device, or the waterseal chamber. As the pleural space is definitively decompressed, the thoracostomy tube will become loculated

from the general pleural space by adhesion of visceral and parietal pleura around it; respiratory variation will then be lost.

3. The character and volume of pleural drainage must be assessed frequently. The significance of diminished drainage volume can only be determined in light of concurrent chest radiographic findings. For example, diminishing sanguinous drainage may mean cessation of bleeding or occlusion of the thoracostomy tube by clot; the chest radiograph will reveal increasing effusion/hemothorax in the latter circumstance, but not the former.
4. Air leaks are apparent as air bubbling through the water seal (not the suction regulator). Small air leaks will demonstrate bubbling only during spontaneous expiration or mechanical inspiration. Large air leaks will demonstrate bubbling through both phases of the respiratory cycle. These so-called continuous air leaks may indicate a bronchopleural fistula or tracheobronchial laceration.

**G. Thoracostomy tube removal**

1. General criteria for thoracostomy tube removal:
  - a. Complete radiographic expansion of the lung.
  - b. Absence of air leak for 24 hours.
  - c. Drainage volume <100 mL over 24 hours.
2. Prepare a dressing of impervious tape, gauze 4 × 4 sponges, petroleum jelly gauze, and povidone-iodine antiseptic ointment.
3. With a sterile scissor, divide the sutures securing the thoracostomy tube.
4. Instruct the patient to take a full inspiration, hold his/her breath, and perform a Valsalva maneuver. Practice this sequence several times.
5. Repeat the above sequence, briskly withdraw the thoracostomy tube with the patient performing a Valsalva maneuver at full inspiration, and immediately apply the occlusive dressing to the thoracostomy wound.
6. Do not close the thoracostomy site with suture or other material.
7. Obtain an immediate portable chest radiograph to ensure the absence of pneumothorax.

**IV. PEDIATRIC CONSIDERATIONS**

- A. Approximate sizes for pediatric thoracostomy tubes by age and weight are shown in Table A9-1.

**Table A9-1. Approximate sizes for pediatric thoracostomy tubes by age and weight**

Age	Approximate Weight (kg)	Tube Size (French)
Newborn to 9 months old	3.5-8	12-18
10 to 17 months old	10	14-20
18 months to 3 years old	12-15	14-24
4 to 7 years old	17-22	20-32
8 years old	28	28-32
≥9 years old	≥35	28-38

Needle thoracostomy can usually be accomplished in infants with a 23-gauge butterfly needle.

**V. PRECAUTIONS/COMPLICATIONS**

- A. Possible injury to intercostal artery, vein, or nerve
- B. Extrapleural tube position
- C. Subcutaneous emphysema
- D. Break in waterseal, resulting in pneumothorax
- E. Chest wall hematoma/ecchymosis
- F. Chest wall or intrapleural hemorrhage
- G. Infection
  - 1. Insertion-site cellulitis
  - 2. Tract infection
  - 3. Empyema
- H. Laceration of diaphragm or intrathoracic/intra-abdominal viscera
- I. Recurrence of pneumothorax (upon removal, secondary to entrained room air or rupture of pulmonary bulla/bleb).
- J. Clamping a chest tube in the presence of an air leak may result in life-threatening tension pneumothorax.

**SUGGESTED READINGS**

- 1. Etoch SW, Bar-Natan MF, Miller FB, Richardson D: Tube thoracostomy. Factors related to complications. *Arch Surg* 1995; 130:521
- 2. Evans JT, Green JD, Carlin PE, Barret LO: Meta-analysis of antibiotics in tube thoracostomy. *Am Surg* 1995; 61:215
- 3. Gregoire J, Deslauriers J: Closed drainage and suction systems. *In: Thoracic Surgery. First Edition.* Pearson FG, Deslauriers J, Ginsberg RJ, et al (Eds). New York, Churchill Livingstone, 1995, pp 1121-1135
- 4. Martino K, Merritt S, Boyaokye K, et al: Prospective randomized trial of thoracostomy removal algorithms. *J Trauma* 1999; 46:369
- 5. Quigley RL: Thoracentesis and chest tube drainage. *Crit Care Clin* 1995; 11:111
- 6. Richardson JD, Spain DA: Injury to the lung and pleura: *In: Trauma. Fourth Edition.* Mattox KL, Feliciano DV, Moore EE (Eds). New York, McGraw-Hill, 2000, pp 523-543
- 7. Wilson RF, Steiger Z: Thoracic trauma: Chest wall and lung. *In: Management of Trauma: Pitfalls and Practice. Second Edition.* Wilson RF, Walt AJ (Eds). Baltimore, Williams & Wilkins, 1996, pp 329-331